A SUPPLEMENT TO Contact Lens SPECTRUM® APRIL 2011

Infiltrative Keratitis in Daily Lens Wearers: Do You See What I See?

Diagnosis, frequency, risk factors and patient management

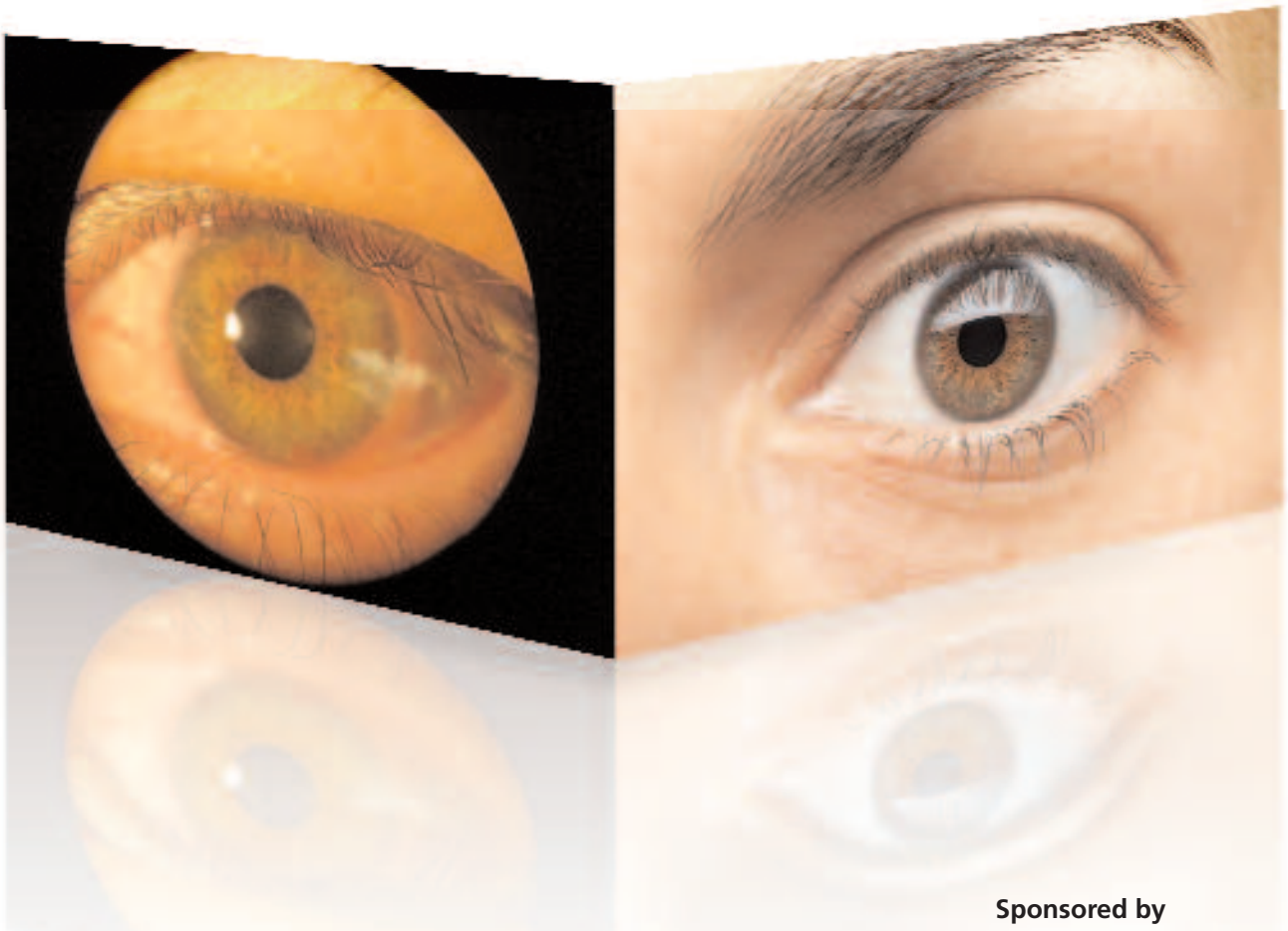

Sponsored by

BAUSCH + LOMB™

PANELISTS

Joseph Shovlin, OD, FAAO, moderator
Dr. Shovlin is in private practice in Scranton, Pa. He is a Fellow of the American Academy of Optometry (AAOpt), a Distinguished Practitioner of the National Academy of Practice in Optometry, and a member of the American Optometric Association (AOA) and the Pennsylvania Optometric Association. He is a Diplomate and Chair of the Section on Cornea and Contact Lenses of the AAOpt, past Chair of the Contact Lens Section of the AOA and a former member of the Ophthalmic Advisory Panel of the FDA. He has been an advisor to AMO and a member of advisory panels for Alcon, Abbott Medical Optics (AMO), Bausch + Lomb and Inspire.

S. Barry Eiden, OD, FAAO
Dr. Eiden is president and medical director of North Suburban Vision Consultants, Ltd., a private group practice specializing in primary eye care, complex contact lens management, treatment of ocular diseases and refractive surgery. He is also co-founder and president of EyeVis Eye and Vision Research Institute. Dr. Eiden is an assistant clinical professor at the University of Illinois at Chicago Medical Center in the Department of Ophthalmology, Cornea and Contact Lens Service and an adjunct faculty member of the Illinois, Salus and UMSL Colleges of Optometry. Dr. Eiden received an honorarium for his participation in this project.

Milton M. Hom, OD, FAAO
Dr. Hom practices in Azusa, Calif., is a Diplomate in Cornea and Contact Lenses, and has written more than 150 publications. He serves on several editorial boards including *Review of Optometry*, *Optometric Management*, *Primary Care Optometry News*, *Review of Cornea and Contact Lenses* and *Optometry Times*. He has more than 25 published abstracts and peer-reviewed papers. Dr. Hom's latest books are Mosby's Ocular Drug Consult and Manual of Contact Lens Prescribing and Fitting, 3rd Edition (Elsevier). Dr. Hom is the AOA CLCS 2010 Luminary Award recipient. He has been an advisor to Allergan, AMO, Bausch + Lomb, Ciba Vision, Coopervision, Essilor and Inspire.

Derek Cunningham, OD, FAAO
Dr. Cunningham is director of optometry at Dell Laser Consultants in Austin, Texas. His research involves retinal drug treatments, glaucoma surgery techniques, ocular surface disease and refractive surgery. He has a special interest in sports vision, and routinely lectures and presents at the National Athletic Trainers Association meeting and the American College of Sports Medicine meetings. He is also a council member for the AOA Sports Vision Section. Dr. Cunningham has been an advisor for Alcon, AMO, Allergan, Bausch + Lomb, Focus Labs, Inspire and Ista. He has been a member of an advisory panel for Allergan, Bausch + Lomb, Focus Labs, Inspire and Ista.

Jeffrey Myers, OD, FAAO
Dr. Myers is the owner and president of Winchester Vision Care in Canal Winchester, Ohio. He graduated from The Ohio State University College of Optometry where he is an adjunct Clinical Assistant Professor. For 22 years, he was an Optometry Consultant at the Chillicothe Veterans Affairs Medical Center. He is a past chair of the EastWest Eye Conference, past president of the Ohio Optometric Association (OOA) and the Ohio Optometric Foundation, and has been recognized as the Warren & Ruth Morris Optometrist of the Year by the OOA. He has been an advisor to Bausch + Lomb.

Andrew Sacco, OD, FAAO
Dr. Sacco is owner of the Sacco Eye Group in upstate New York, a two-doctor private practice with an emphasis in ocular disease and clinical research. Dr. Sacco is a graduate of the Pennsylvania College of Optometry. He completed a residency in ocular disease/primary care at The Eye Institute in Philadelphia. Dr. Sacco has held various executive positions with the New York State Optometric Association and has served on several committees with the AOA. Dr. Sacco is on staff at two hospitals, and is a clinical educator in ocular disease at the Family Practice Residency program at the Johnson City Family Care Center in Johnson City, NY. He has been an advisor to Bausch + Lomb, and received research funding from Bausch + Lomb and Vistakon.

Mary Jo Stiegemeier, OD, FAAO
Dr. Stiegemeier is in private practice in Beachwood and Hudson, Ohio, where she specializes in contact lens fitting. She is a graduate of The Ohio State University College of Optometry, where she earned the Bausch and Lomb Contact Lens Award. Dr. Stiegemeier was also presented with a Distinguished Teaching Award from Mt. Sinai Hospital, Cleveland. She is the 2009 recipient of the American Optometric Association Cornea and Contact Lens Section Luminary Award. Dr. Stiegemeier is one of the founding board members of Women of Vision, an organization dedicated to helping female optometrists. She has received research funding from Bausch + Lomb.

Contact Lens SPECTRUM®

Editorial Staff
EDITOR, *CONTACT LENS SPECTRUM*: Jason J. Nichols, OD, MPH, PhD, FAAO
EDITORIAL MANAGER, SPECIAL PROJECTS: Angela Jackson
EDITOR/PROJECT MANAGER, SPECIAL PROJECTS: Leslie Goldberg

Design and Production
PRODUCTION DIRECTOR: Leslie Caruso
PRODUCTION MANAGER: Bill Hallman
ART DIRECTOR: Michael F. Higgins

Editorial and Production Offices
323 Norristown Road, Suite 200, Ambler, PA 19002
Phone: (215) 646-8700

Business Staff
GROUP PUBLISHER: Roger T. Zimmer
ACCOUNT EXECUTIVE: Dawn E. Schaefer
MARKETING MANAGER: Amy Wauhop
PROMOTIONAL EVENTS MANAGER: Michelle Kieffer
CIRCULATION DIRECTOR: Deb Benward

Copyright 2011. Wolters Kluwer Pharma Solutions, Inc. All Rights Reserved.

Infiltrative Keratitis in Daily Lens Wearers: Do You See What I See?

Diagnosis, frequency, risk factors and patient management

Dr. Shovlin: The issue of infiltrative keratitis during contact lens wear has been a topic I've been interested in for several years. Recently, there has been a great deal of discussion among colleagues, in the literature and at conferences regarding an increase in the rate of sterile infiltrative keratitis, especially in daily lens wearers, and potential factors associated with this increase (Carnt, 2009; Diec, 2009; Hine, 2008; Kislan, 2010; Reeder, 2011; Reindel, 2009; Szczotka-Flynn, 2010). To further discuss these recent findings, a group of clinicians, including myself, convened to present cases (Table 1) of infiltrative keratitis in daily lens wearers. We will discuss diagnosis, frequency, risk factors and patient management to increase awareness and help our colleagues manage these interesting cases.

Case criteria included daily lens wearers with a common presentation, at least one sign or symptom, and multiple infiltrates of a noninfectious etiology who presented within the last 2 years. Of the cases identified and submitted by the participants, 5 cases were chosen to reflect a range of presentations, patient characteristics and post-treatment patient management.

Case 1. Female Silicone Hydrogel Daily Lens Wearer with Multiple Peripheral Infiltrates (Figure 1)

A 38-year-old female daily lens wearer presented with hyperemia, pain, photophobia and reduced visual acuity OS. Slit lamp examination showed more than 10 focal and diffuse infiltrates of variable size around the clock, edema and trace anterior chamber reaction. She wore senofilcon A lenses and indicated she used "the green bottle" of care solution, although the exact solution was not confirmed. Treatment included discontinuation of lens wear and Zylet (Bausch + Lomb) q2h for 3 days in the affected eye. At follow-up 3 days later, symptoms had resolved but acuity was still reduced. Treatment with Zylet QID was advised for 2 weeks, followed by Lotemax (Bausch + Lomb) QID for 2 more weeks. Following complete resolution, we performed LASIK for vision correction. To date, there has been no recurrence.

Case 2. Female with Bilateral Central and Mid-peripheral Infiltrates and Reduced Visual Acuity (Figure 2)

A 46-year-old female daily contact lens wearer presented for an urgent care visit with complaints of burning in both eyes and reduced vision. Prior to the visit, she had stopped contact lens wear for several days and symptoms resolved; they promptly returned with resumption of lens wear. Other than mild hyperemia, her external examination was unremarkable. Slit lamp examination revealed diffuse, centrally and mid-peripherally located anterior stromal infiltrates with no overlying fluorescein staining OD. Superficial punctate keratitis (SPK) OS was noted but no infiltrates were observed OS. The lenses worn at onset were balafilcon A and she reported using Opti-Free Replenish (Alcon) consistently for several years and performed digital rubbing to clean lenses nightly. Discontinuation from lens wear was advised and she was treated with Tobradex (Alcon) QID for 7 days with a 1-week follow-up examination. At follow up, visual acuity was 20/20 OD and OS and corneas were clear. She was instructed to resume daily wear with a new pair of balafilcon A lenses and switch to Clear Care (Ciba Vision) solution. She has been followed for more than 1 year without recurrence.

Case 3. Female College Student with Poor Lens Hygiene and Lens Over Wear

A 19-year-old female college student presented for an emergency visit complaining of moderate pain and significant photophobia. In addition to reduced visual acuity and moderate injection in each eye, slit lamp revealed bilateral gray, granular, small, multiple/diffuse, nonstaining epithelial and subepithelial infiltrates located mainly in the central corneas but some were also located in the periphery. At onset, she wore senofilcon A daily wear lenses and used Opti-Free Replenish for disinfection and storage. She admitted that she never rubs her lenses or rinses "much" at night during the cleaning and disinfection process. Treatment included discontinuation from lens wear and treatment with Tobradex OD and OS QID for 7 days. At follow-up, she had complete resolution of signs and symptoms and visual acuity was 20/20 in both eyes. Contact lens wear was resumed with a new pair of lenses (senofilcon A) for daily wear and her disinfection regimen was changed to a hydrogen peroxide system with a nonpreserved saline rinse. No recurrence has been observed in the 2 weeks subsequent to her follow-up visit.

Case 4. Female Daily Silicone Hydrogel SiHy Lens Wearer Using a Private Label Cleaning System

A 21-year-old female college student presented with reduced visual acuity OD, and photophobia and mild hyperemia in both eyes. Prior to the visit, the patient reported having symptoms for "2 to 3 weeks." She reported headaches but was otherwise healthy and her external exam was unremarkable. Slit lamp exam revealed 6-10 small, white, granular, focal infiltrates across both corneas. She wore galyfilcon A lenses at onset of symptoms and used an unknown private label lens care solution to reduce costs. Lens wear was discontinued and she was treated with Pred Forte (Allergan) TID OD and OS until follow-up 4 days later. At follow-up, visual acuity was still reduced OD (20/30) but resolution of all other signs and symptoms was complete. She was refitted with omafilcon A for daily wear and instructed to use Complete Easy Rub (AMO) for storage and disinfection. No recurrence has been observed for over 4-5 months.

Case 5. Male High School Student Daily Wear Silicone Hydrogel Lens and Opti-Free Replenish User

A 15-year-old male high school student presented with trace injection bilaterally but without concomitant symptoms or reduced acuity. Slit lamp revealed multiple (15 OD and 20-30 OS), diffuse, small, round, gray, granular infiltrates across the entire cornea. The patient had been wearing galyfilcon A lenses on a DW basis and used Opti-Free Replenish for storage and disinfection. Lens wear was discontinued and he was treated with Tobradex OD and OS QID for 7 days, when he was to return for follow up. At the follow-up visit, complete resolutions of signs were noted and he was refitted with nelfilcon A daily disposables lenses. No recurrence has occurred in the 6 weeks since follow up.

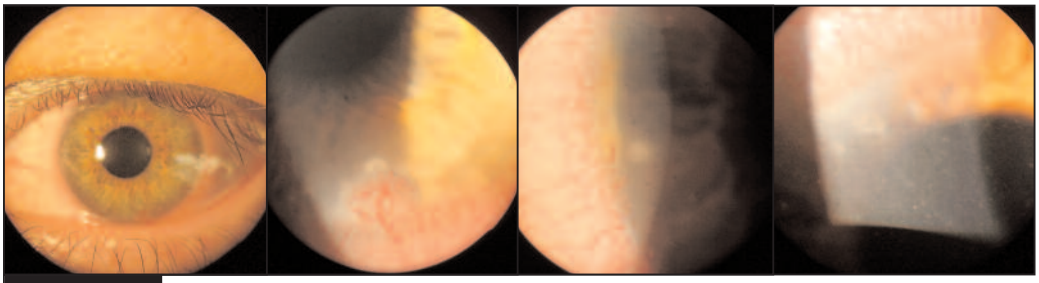

Figue 1

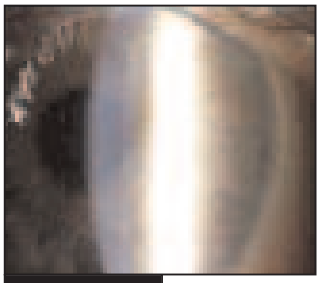

Figue 2

Dr. Shovlin: Are the infiltrative keratitis cases presented here similar to what you experience in your practice with contact lens wearers?

Dr. Eiden: Infiltrative keratitis cases seen in our practice vary quite a bit. The most common form present with multiple, small, sub-epithelial infiltrates with red eye and irritation, such as that seen in the second and third cases presented. Severity varies from mild — almost asymptomatic — to very irritated, red eyes with photophobia and loss of contact lens tolerance. Single infiltrates, like that of case one, are most commonly found with continuous wear — irrespective of soft contact lens material — are peripherally located, and have some degree of epithelial defect ranging from superficial overlying staining to frank ulceration.

Dr. Stiegemeier: Typically, the patients I've been seeing are the same as the cases presented with diffuse infiltrates that cover the entire cornea.

Dr. Sacco: Over the past several years, I've been seeing central or paracentral, focal, granular epithelial or anterior stromal infiltrates without overlying stain or evidence of infectious etiology or hypoxic risk factors. This is consistent with many of my colleagues in the area where I practice.

Dr. Shovlin: What would you say is the classic presentation of infiltrative keratitis in daily wear contact lens wearers? Are they symptomatic versus asymptomatic?

Dr. Sacco: An uncomfortable eye, redness, perhaps photophobia, with 5-15 central focal, grayish-white, granular, nonstaining infiltrates without lymph node involvement in daily lens wearers who have been in lenses for years.

Dr. Cunningham: Typically sectoral or circumferential limbal redness, slightly decreased acuity and eye pain and unlike most other infiltrative events such as those seen in continuous wear, there are multiple superficial infiltrates, typically occurring in experienced lens wearers.

Dr. Stiegemeier: Maybe 70% symptomatic with vague symptoms, trace injection and diffuse, round, white infiltrates with occasional light sensitivity and 30% asymptomatic. However, many times a patient comes in and doesn't complain, eye's white, and then I look in the slit lamp and ask if they ever experience burning on lens insertion or other symptoms and they say "yes." So that patient is symptomatic even though outward signs may be lacking. So it's hard to say whether patients really are asymptomatic or if we simply aren't digging deeply enough and asking the right questions.

Dr. Shovlin: I've had the same experience. I ask patients if their eyes have been red and recovered with a simple hiatus from lens wear and they often answer: "yes."

Dr. Shovlin: ***How do you diagnose the types of infiltrates presented in the cases we discussed? What ICD-9 codes do you use?***

Dr. Eiden: We look at number and location of infiltrates, and the presence or absence of an epithelial defect, anterior chamber reaction, and photophobia. Additional factors assessed include visual acuity, presence/absence of discharge (mucopurulent or watery), and degree of pain. Since no specific ICD-9 code exists for contact lens-associated corneal infiltrates or infiltrative keratitis, we use several codes that identify the underlying inflammatory condition (Table 2).

Dr. Sacco: Clinical presentation, presence/absence of staining, a lack of hypoxic causes, assess fit is adequate/not too tight, and re-affirm that the patient's compliant, typically noting 371.82 (Table 2). In noncompliant patients the diagnosis is not as clear cut. We follow up, and if the infiltrates resolve and don't recur with new solutions, we'll attribute it to the disinfectant/lens combination.

Dr. Myers: I describe location and number, typically multiple, diffuse infiltrates. The ICD-9 most commonly used is 370.52 (Table 2). Other ICD-9 codes might be appropriate depending on clinical findings (Table 2). Several codes exist for a true ulcer, but that is a completely different presentation. This is one of the biggest problems with diagnosing infiltrates, there is not a specific ICD code for them so it is difficult to say which one is really best and/or more accurately describes this type of infiltrative event.

Dr. Shovlin: What differentials would you use to diagnose between infiltrative keratitis associated with contact lenses and microbial keratitis?

Dr. Sacco: Primarily pain, location, degree of redness and presence of staining.

Dr. Cunningham: Breaks in the epithelium, anterior chamber reaction and peripheral inflammation. Inflammation tends to be gray in these infiltrates whereas an ulcer tends to be white due to necrosis.

Dr. Stiegemeier: Slit lamp signs, types of discharge and the duration of event. Since the symptoms in patients with microbial keratitis come on very quickly, patients typically come in sooner than patients with infiltrative keratitis or other sterile infiltrative events.

Dr. Myers: I find a lack of discharge and more infiltrates in patients with infiltrative keratitis associated with SiHys and multipurpose solutions (MPS). I typically find edema, more conjunctival hyperemia and more staining in microbial keratitis.

Dr. Hom: I think if one depends on the appearance of staining, it can get you in a lot of trouble. Both sterile and infectious infiltrates will stain with fluorescein when they are in their active state. Sometimes, an infectious infiltrate won't stain at the very early stages. Staining is often the most confusing sign for differential diagnosis. I have much better success with anterior chamber reaction as a differential sign. If it's present, then I treat it as infectious.

Dr. Shovlin: One other important point is that in microbial keratitis, the size of the infiltrate is generally larger than what we see with a sterile infiltra-

continued on page 7

Table 1. Case study characteristics and baseline data					
	Case 1	**Case 2**	**Case 3**	**Case 4**	**Case 5**
Age, y; Gender, M/F	38 y; F	46 y; F	19 y; F	21 y; F	15 y; M
Occupation	Accountant	Unknown	College student	College student	High school student
Eye	OS	OD & OS	OD & OS	OD & OS	OD>OS
Symptom duration (prior to visit)	Weeks	Several weeks	2 days	14-21 days	N/A; no symptoms
Visual acuity	20/30 OS	20/25 OD & OS	20/30+ OD; 20/30- OS	20/30- OD; 20/50 OS	20/20 OD & OS
Infiltrate location	Around the clock	Central and mid-peripheral OD	Central 6 mm extending somewhat to the peripheral cornea OD & OS	Diffuse OD & OS	Diffuse across cornea OD & OS
Infiltrate number, size, and appearance	More than 10 focal and diffuse infiltrates of variable size	Several small, diffuse, granular infiltrates OD	Gray, somewhat granular, small (<0.5 mm), multiple/diffuse epithelial/subepithelial infiltrates without staining OD & OS	6-10 small, white, granular, focal infiltrates OD & OS	15 OD; 20-30 OS gray, granular, small, round infiltrates
Injection (ie, +1 [mild]/+2 [moderate]/+3 [severe])	+2 OS	+1 OD & OS	+2 OD & OS	+1 OD & OS	+1 OD & OS
Symptomology (eg, pain, photophobia, discharge, edema, or anterior chamber rxn)	Pain, photophobia, edema, and trace anterior chamber reaction	Burning	Moderate pain; significant photophobia	Photophobia	None
Lens and Lens care					
Lens at onset	Senofilcon A (Acuvue Oasys; Vistakon)	Balafilcon A (PureVision; Bausch + Lomb)	Senofilcon A (Acuvue Oasys)	Galyfilcon A (Acuvue Advance for Astigmatism; Vistakon) OD & OS	Galyfilcon A (Acuvue Advance; Vistakon)
Modality and typical wearing time/day (hours/day)	daily wear; 12-14 hours/day	daily wear; daily wear time not noted	daily wear; ≈16-18 hours/day	daily wear; 16 hours/day	daily wear; daily wear time not noted
Lens age	1 month	Unknown	1 week	<14 days	Unknown
Care Solution at onset	'Green bottle' (unknown)	Opti-Free Replenish	Opti-Free Replenish	Private Label – unknown	Opti-Free Replenish
Post-treatment lens	N/A; LASIK	Balafilcon A (PureVision)	Senofilcon A (Acuvue Oasys)	Omafilcon A (CooperVision Proclear Toric)	Nelfilcon A (CIBA Dailies AquaComfort Plus)
Care Solution post-treatment	N/A	Clear Care	Clear Care with nonpreserved saline rinse	Complete Easy Rub	N/A
Differential diagnosis	• Chlamydial keratoconjunctivitis • Adenoviral keratoconjunctivitis • Thygeson's superficial punctate keratopathy (SPK)	• Infiltrative keratitis • Viral conjunctivitis	• Thygeson's SPK • Viral conjunctivitis (adenoviral or Epstein-Barr) • Contact lens-associated red eye (CLARE) • Infiltrative keratitis	• Infiltrative keratitis • Hyperemia of conjunctiva • Allergic conjunctivitis • Viral conjunctivitis	• Infiltrative keratitis • Epidemic keratoconjunctivitis (EKC) • Thygeson's SPK
Final diagnosis	Infiltrative keratitis secondary to contact lens wear (370.59)	Corneal opacity, central (371.03) due to silicone hydrogel/Opti-Free Replenish incompatibility; corneal disorder, due to contact lens (371.82); punctate keratitis, corneal (370.21)	Corneal opacity, central (371.03); corneal disorder, due to contact lens (371.82)	Other interstitial & deep keratitis (370.59)	Infiltrates due to care solution sensitivity (370.20 and 077.1)

Table 2. Differential diagnosis between infiltrative conditions and corresponding 2011 ICD-9 codes.*

Etiology	High probability of sterile infiltrative keratitis attributed to contact lens wear without loss of vision or surgical intervention attributed to event			
Clinical entity	Contact lens-associated infiltrates/infiltrative keratitis (CLAIK)	Infiltrative keratitis (IK)	Contact lens-associated red eye (CLARE)	Contact lens peripheral ulcer (CLPU)
Eye involved	Typically bilateral	Unilateral	Unilateral	Unilateral
Clinical course	Sudden onset, but when questioned, patient will often report multiple milder episodes of redness, managed by CL removal for several days; may be self-limiting	Onset may be sudden or over a period of days, may be self-limiting in non-CL wearers or with lens discontinuation in CL wearers	Sudden onset often upon waking	Increasing pain, redness and photophobia over several days
Gross signs and symptoms	In symptomatic patients: mildly reduced visual acuity, mild-to-moderate photophobia (though can be significant in some cases), discomfort (burning) or pain	Mild-to-moderate symptoms (occasionally asymptomatic) including redness, photophobia, blurred vision, irritation, occasional discharge	Moderate-to-severe pain, copious tearing, extreme photophobia, intense injection upon waking	Discomfort, foreign body sensation, itching, pain, photophobia, tearing/discharge, redness, blurred vision (can be asymptomatic in some cases)
Number and location of infiltrates	Multiple, diffuse infiltrates central, paracentral, or entire cornea	Usually single, peripheral/mid-peripheral cornea	Multiple infiltrates (up to 60, 2-3 mm from limbus)	Single peripheral/ mid-peripheral ulcer
Appearance of infiltrates	Small course, grainy/granular and gray opacities that are epithelial or subepithelial (in rare cases, may be anterior stromal)	Small, round, hazy, gray-white, cloudy, or amorphous opacities that may be subepithelial or anterior stromal	Small focal or diffuse, round white infiltrates	Between 1-2 mm, white, more delineated in appearance with sharp edges. Often with stromal edema surrounding the infiltrate
Slit lamp findings (noninfiltrate)	No overlying NaFl staining or edema	Epithelial defect (overlying staining) may/may not be present, edema	Epithelial defect (overlying staining) may/may not be present, edema	Overlying NaFl staining of epithelial defect, edema, necrosis of anterior stroma
Modality	Daily wear in all but a few cases	More common in extended wear, also in daily wear	Extended wear, continuous wear	Most commonly extended wear, continuous wear
ICD-9 Codes	371.82, 371.03, and 370.52 or 370.20 • If injected: 370.40 or 370.49	371.24, 371.02, and 370.20 • If injected: 370.40 or 370.49	371.24, 370.40 or 370.49, 371.02, and 379.93	370.01
Notes	• 371.24 typically does not apply to CLAIK as edema is rarely present • Can also add symptom codes listed below	• If edema absent use 371.82 instead of 371.24 • Can also add symptom codes listed below	• Use 371.82 instead of 371.24 if edema is absent • Can also add symptom codes listed below	No additional codes required — use only if frank ulceration present

Diagnostic codes

Complication due to contact lens: if edema present: 371.24 – Corneal edema due to wearing of contact lenses; if edema absent: 371.82 – Corneal disorder due to contact lens

Ulcers: 370.00 – Corneal ulcer, unspecified; 370.01 – Marginal corneal ulcer; 370.03 – Central corneal ulcer

Keratitis: 370.20 – Superficial keratitis, unspecified; 370.21 – Punctate keratitis (Thygeson's SPK); 370.50 – Interstitial keratitis NOS; 370.52 – Diffuse interstitial keratitis (also used for Cogan's syndrome); 370.59 – Other interstitial and deep keratitis; 370.80 – Other forms of keratitis

Keratoconjunctivitis/conjunctivitis: 370.40 – Keratoconjunctivitis, unspecified (superficial keratitis with conjunctivitis NOS); 370.49 – Other keratoconjunctivitis; 372.30 – Conjunctivitis, unspecified

Presence of infiltrates (opacities): 371.02 – Peripheral opacity of cornea; 371.03 – Central opacity of cornea

Viral etiology: 077.1 – Epidemic keratoconjunctivitis (most common serotypes: adenovirus 8, 19, and 37; less frequent serotypes: 2-5, 7, 9, 10, 11, 14, 16, 21, 29); 077.3 – Other adenoviral conjunctivitis (non-EKC serotypes)

Symptom and sign codes

Photophobia: 368.13 – Visual discomfort

Tearing: 375.21 – Epiphora due to excess lacrimation

Pain: 379.91 – Pain in or around eye

Hyperemia/Discharge: 379.93 – Redness or discharge of eye

Unknown Etiology	High probability of microbial keratitis (MK)	
Thygeson's superficial punctate keratopathy (SPK)	Nonviral	Epidemic keratoconjunctivitis (EKC)/adenoviral
Typically bilateral	Unilateral	Typically bilateral
Chronic, remittent course	Sudden onset of signs and symptoms	Sudden onset of symptoms, infiltrates present ≈7 days after (rule of 8)
Visual acuity normal or mildly reduced, only mild-to-moderate foreign body sensation, tearing, occasional photophobia, eye appears normal, little or no blepharitis, conjunctival injection, or corneal edema	Severe pain (disproportionate to signs in *Acanthameoba* keratitis [AK]), photophobia, redness, mucopurulent discharge, blurred vision	Acute follicular conjunctivitis, hyperemia, soreness, photophobia, excessive tearing, "pointy lashes", foreign body sensation, blepharitis, blurred vision, palpable pre-auricular nodes, recent cold symptoms
Numerous central opacities	May be central or peripheral, stromal ring infiltrate (AK)	Multiple, diffuse central infiltrates
Round or stellate areas of coarse gray, slightly elevated intraepithelial opacities - resemble subepithelial infiltrates, but are more superficial, duller in color, and less organized	Suppurative stromal infiltrate (often >1 mm) with indistinct edges, snowflake or globular appearance	Vary from pale to hazy white or whitish gray infiltrates with indistinct edges. Rarely peripheral, often very central and usually do not stain
No anterior chamber reaction, NaFl staining may be of a "negative" pattern. Lesions are epithelial with very slight elevation	Anterior chamber involvement with flare or hypopyon, edema, NaFl staining	Diffuse, fine, superficial keratitis to subepithelial opacities, edema
Not associated with contact lens wear	Currently, most often with extended wear	Not associated with contact lens wear
370.21	370.00 • If hypopyon: 364.05	077.1 and 372.30 • If non-EKC serotype use 077.3 instead of 077.1
No additional codes required	Area of corneal epithelial tissue loss associated w/ inflammation usually caused by microbes	No additional codes required

*Additional articles that may be helpful for differential diagnosis include:

Edwards K, et al. Microbial keratitis and silicone hydrogel lenses. *Contact Lens Spectrum*. January 2004.

Fonn D. Managing silicone hydrogel complications. *Review of Optometry*. July 2002.

Shovlin JP. A differential diagnosis. *Review of Optometry*. February 2011.

continued from page 4

tive event, is often a single isolated opacity of infiltrative cells, and generally located in the central or mid-peripheral cornea.

Dr. Shovlin: What signs and symptoms may help to differentiate viral events from those described in cases 2 through 5?

Dr. Eiden: I look for multiple diffuse subepithelial infiltrates, pre-auricular lymphadenopathy, sore throat, and perhaps other recent viral symptoms. I also ask if other family members recently had similar eye inflammations/infections or systemic viral infections. If we believe adenoviral is the etiology, we confirm by testing with the RPS Adeno Detector (Rapid Pathogen Screening, Inc.).

Dr. Sacco: Also, a viral infection usually will start in one eye and then travel to the other. I palpate the pre-auricular nodes on every infiltrate patient whether I think it is viral or not to be sure.

Dr. Cunningham: Presence of pre-auricular lymphadenopathy as well as watery discharge.

Dr. Myers: I usually see a much redder conjunctiva, epithelial corneal involvement, a much longer presentation, and more pain in viral infections.

Dr. Shovlin: The time course is important. Infiltrates post-viral tend to run later than the acute red eye response as infiltrates are not seen until after a week. Certainly there can be overlap. I also look for "pointy lashes," which is highly suggestive of adenoviral disease.

Dr. Shovlin: Do you believe the types of infiltrates seen in the second through fifth cases we reviewed fit into the current classification system, such as that described by Sweeney and colleagues at the Cornea and Contact Lens Research Unit (CCLRU) (Table 3)? Or is this a different entity? What do you call them?

Dr. Stiegemeier: No, in my opinion, these types of central infiltrates with the concomitant signs and symptoms do not fit in the current classification (Table 3). I believe this is a different entity from the infiltrative events we typically saw in prior years. I call them "solution sensitivity infiltrative events."

Dr. Sacco: I believe this is a new entity and isn't accurately described in the classification system described by Sweeney in 2003 (Table 3) or previously described in the literature for sterile infiltrates. In our office, we previously labeled them "contact lens-associated corneal infiltrates" but I now prefer "contact lens-associated infiltrate/infiltrative keratitis or CLAIK."

Dr. Shovlin: I agree with Dr. Sacco that CLAIK is an appropriate name for this entity. Does CLAIK seem appropriate to describe this entity?

Table 3. Cornea and Contact Lens Research Unit classification of infiltrative events with contact lens wear

Classification	Characteristics
Microbial keratitis (MK)	Ulceration deep into the stroma with infiltration and necrosis of tissue **Appearance:** focal infiltrates usually large (> 1 mm) and irregular with small satellite lesions and significant diffuse infiltration **Location:** central or paracentral cornea **Symptoms:** rapid onset of moderate-to-severe pain and photophobia with severe limbal and bulbar redness, discharge (mucopurulent or purulent), tearing, eyelid edema, and decreased visual acuity
Contact lens–induced peripheral ulcer (CLPU)	Focal ulceration of the epithelium with infiltration and necrosis of the anterior stroma (active phase) **Appearance:** single, small (≤2 mm), well defined (circular), focal infiltrate(s) with slight diffuse infiltration surrounding the lesion **Location:** mid-peripheral to peripheral cornea **Symptoms:** Common: moderate-to-severe irritation, pain, or foreign body sensation with limbal and bulbar redness, and tearing; Less commonly: asymptomatic
Contact lens–induced acute red eye (CLARE)	Inflammation involving both cornea and conjunctiva **Appearance:** multiple, small, focal infiltrates and diffuse infiltration; overlying staining of infiltrates typically absent **Location:** mid-peripheral to peripheral cornea **Symptoms:** irritation to moderate pain and photophobia with moderate-to-severe circumferential redness and tearing; patients often awakened by or notice symptoms shortly after waking
Infiltrative keratitis (IK)	Anterior stromal infiltration with possible epithelial involvement **Appearance:** small, possibly multiple infiltrates, mild-to-moderate diffuse infiltration may be present **Located:** mid-peripheral to peripheral cornea **Symptoms:** mild-to-moderate irritation with redness and discharge (occasionally)
Asymptomatic infiltrative keratitis (AIK)	Infiltration of the cornea **Appearance:** small, focal infiltrates (≤0.4 mm) mild-to-moderate diffuse infiltration; possible superficial punctate fluorescein staining **Located:** peripheral cornea **Symptoms:** asymptomatic; sometimes mild-to-moderate limbal and bulbar redness present
Asymptomatic infiltrates (AI)	**Appearance:** Very small, focal infiltrates (0.2 mm) and/or mild diffuse infiltration; no overlying fluorescein staining **Location:** commonly peripheral but can be across entire cornea **Symptoms:** no signs or symptoms

Sweeney DF, Jalbert I, Covey M, et al. *Cornea.* 2003;22:435-442.

Dr. Cunningham: Yes, I think this is an appropriate name for it.

Dr. Myers: Sure, I think this fits this entity.

FREQUENCY

Dr. Shovlin: How often do you see cases of infiltrates in daily contact lens wearers? Are the types of cases presented today common in your practice? If so, how often do you see them and how impactful are they for the overall practice?

Dr. Myers: Yes, these cases are similar to what we see probably 2 to 3 times a month. They impact what lenses we fit and solutions we recommend for our patients.

Dr. Eiden: Since our practice is oriented to anterior segment eye disease and specialty contact lens management, at least 60% of our patients wear some type of contact lens. As such, our experience with infiltrative events is significant and we typically see a handful per week consisting of both peripheral infiltrative keratitis and CLAIK. Again, the probable care solution sensitivity cases are more common than the isolated peripheral infiltrate cases often seen with continuous wear. They're quite impactful in that we think that we're able to differentially diagnose these and manage them successfully. This creates great confidence in our patients regarding our ability to care for their eye and vision problems.

Dr. Sacco: I see cases several times a month, between 3 and 8 perhaps. Cases 2 through 5 are common in the sense that we've started looking aggressively for these types of cases to prevent future occurrences. They influence lens/care solution combinations we initially prescribe for our patients and our lens/care solution recommendations after resolution of infiltrative keratitis.

Dr. Cunningham: Typically once to twice a week. These infiltrative keratitis cases are a big factor for discontinuation of contact lens wear and a driving force for patients to pursue LASIK.

Dr. Shovlin: Are these cases presented today typical of those you've seen throughout your years of clinical practice? If not, when do you feel you began to see an increase in the number of the types seen in cases two through five?

Dr. Sacco: I didn't see them prior to early/mid 2007. We noted an increase after 2008 into 2009.

Dr. Cunningham: We've also seen a small jump in the last year or two. While I've observed peripheral infiltrates as long as I've practiced, I can't say the same for the central infiltrates.

Dr. Myers: The contact lens associated infiltrative keratitis cases in the last few years are more frequent and different than those seen previously, which we started seeing in 2006.

Dr. Stiegemeier: Cases two through five are reminiscent of the infiltrates I saw in the mid to late 80s as a response to some of the preservatives within specific solutions at that time. They had decreased but now we're seeing a resurgence, which may be due to a confluence of various factors. Until a true etiology is known and confirmed we may have a recurring situation with these infiltrates.

Dr. Shovlin: My experience mirrors Dr. Stiegemeier's description. I don't think they're a new phenomenon — I've been seeing them for the past 10 to 15 years (Yeung, 1997).

Dr. Shovlin: Many colleagues reported not seeing an increase in sterile infiltrates in general or CLAIK. Do you feel this condition is being misdiagnosed or ECPs may be missing it if they aren't looking for it?

Dr. Eiden: Yes, many are misdiagnosed—especially as epidemic keratoconjunctivitis (EKC), if they don't see it that often. However, if they're contact lens- and care solution-related, they'll be recurrent in a short time period and a correct diagnosis can be made. As is always true in health care, you don't diagnose things that you don't look for.

Dr. Myers: Again, it's possible they're missing it because the subepithelial

infiltrates are subtle, and if the eyecare practitioner has already made a diagnosis in his mind before examining the patient, he might not look carefully at the cornea and would miss this or misdiagnose.

Dr. Shovlin: Additionally, I believe that due to the self-limiting nature of CLAIK, asymptomatic patients may often be missed. I recently read an article where they described a problem being seen in MPS users that sounds distinctly like CLAIK and says it resembles Thygeson's SPK (Ventocilla, 2010), so in some cases, CLAIK may be misdiagnosed as Thygeson's. Furthermore, I think there are geographic factors that may be at play, including differences in microbes present in the water supply or allergies, which may prime the immune system, so it readily reacts to something in the MPS and/or lens material. This is a sort of two-hit model that is commonly observed in the innate immune system (Ausubel, 2005).

RISK FACTORS AND AVOIDANCE

Dr. Shovlin: If there is indeed an increase, what do you believe is responsible for the increase in the number of overall infiltrative cases? What are the commonalities you have found among the cases of CLAIK that you see in your practice?

Dr. Hom: I think tight lenses are a big factor. Based on my clinical experience, some lenses generally tighten in about 1 week's time.

Dr. Sacco: My experience has been the same as what has been reported in the literature with SiHy lenses (Carnt, 2009; Diec, 2009; Kislan, 2010; Reeder, 2011), more commonly Acuvue Oasys (Johnson & Johnson) and Opti-Free Replenish (Alcon). I believe some of these patients may not be rubbing their lenses as well.

Dr. Myers: Until late 2007 or early 2008, we were a heavy user of Opti-Free Replenish and Acuvue Oasys, and we saw a lot of these cases. In our first 90 cases in our practice, we saw 50% more cases with Johnson & Johnson SiHys than we would expect based upon sales. Opti-Free Replenish care solution was the other commonality, being the care solution in about two-thirds of the cases. But we moved away from using Replenish and Oasys lenses and saw a decrease. We see few of our own patients with these issues now, and are primarily seeing patients from other practices with the issue. Also, patient noncompliance with solutions plays a role.

Dr. Stiegemeier: There has been an increase with SiHy lenses and certain solutions, but we have seen them with all lens materials and MPS.

Dr. Shovlin: I would agree with Dr. Stiegemeier that a disproportionate number is seen with certain lens/care solution combinations but I have seen this entity with all multipurpose solutions.

Dr. Shovlin: Do you think the higher rate is due to the increased market share of SiHy lenses?

Dr. Eiden: This is most likely a factor in total numbers of cases, but some SiHys may have material characteristics that could influence these events, and this must be examined carefully.

Dr. Shovlin: Why do you think this is seen in only some wearers and not others using the same products?

Dr. Cunningham: I think this is a case of typical immune system variability.

Dr. Myers: I think it is still unknown and more work needs to be done to determine exactly why only some lens wearers have a problem even if they use the same lenses or care solution. Perhaps there is some other precipitating factor that is not yet known. Or, perhaps, it's simply a delayed hypersensitivity reaction, and with that condition, some people will react and some people won't (Hong, 2009). I think, in many cases, it's a delayed hypersensitivity reaction to the TearGlyde molecule in Opti-Free Replenish, since it is one of the two components that differ between Opti-Free Replenish and Opti-Free Express (Alcon), and in my opinion, we haven't seen a problem of this magnitude with Express.

Dr. Shovlin: Unfortunately, the cause is speculative until it can be replicated with consistency or evaluated through a clinical assessment. I'm in the camp that believes toll-like receptors are recognizing bacterial components, especially lipopolysaccahride (LPS), and upregulating the innate immune response. Certain care solutions do poorly against certain secondary pathogens that are less likely to cause frank infection but rather a florid inflammatory response. This whole cascade might be aggravated by poor tear exchange and deposition with certain lenses.

Dr. Shovlin: What do you think is stimulating the inflammatory reaction? Based on the recently published LASH study (Szczotka-Flynn, 2010), bioburden is a significant risk factor for infiltrative events during continuous wear; do you feel that it also plays a role in daily wear patients? Do you believe that these infiltrative events are truly sterile and the bioburden is from dead rather than live microbes?

Dr. Sacco: Maybe bioburden or protein deposition, which adds to the bioburden? Perhaps the material holds a care solution component, then releases it or other causative agents. I'm just not sure at this point.

Dr. Cunningham: My thoughts are that it's an immune response to mechanical and chemical interactions of lenses and/or solutions. And while I believe the infiltrate is sterile, it will likely have a biological cause, often due to bacterial components or various proteins from other microbes.

Dr. Eiden: Yes, in some cases I surely agree that this is a significant factor, especially in cases of continuous wear patients, where there is the sewer effect under the lens and build up of the bioburden. However, I'm not sure this plays a role in the multiple infiltrate response that we see with MPS users.

Dr. Hom: I think bioburden may play a role but I think they could be associated with bacteria in some cases or most cases. I think exotoxins may play a role, though this is not the exclusive factor, but can be a contributing factor.

Dr. Shovlin: I'm not completely sold on it being 'sterile' as not all MPS are effective against certain bacteria found in contaminated lens cases, like *Stenotrophomonas maltophilia* (Nikolic, 2010), but this may just be opportunistic and cause inflammation rather than infection in healthy individuals who have not undergone ocular surgery.

Dr. Shovlin: Do you think that CLAIK is a result of noncompliance? What aspects of compliance do you feel are most impactful and how can we improve this? Do you ask your patients if they wash their hands and their cases? Do you ask how they wash their hands and lens cases?

Dr. Stiegemeier: No. I don't feel that it is in CLAIK. I think extended wear infiltrates are from noncompliance.

Dr. Eiden: It depends on how you define noncompliance. If you're talking about patients who wear their daily wear lenses overnight regularly, don't properly clean and disinfect, or obtain lenses without professional care and assessment, then yes for sure. I think daily removal of lenses would be most impactful; followed by proper lens handling hygiene, such as always

Table 4. Characteristics of contact lens-associated infiltrates/infiltrative keratitis					
Presentation	**Diagnosis**	**Frequency**	**Initial Observation**	**Risk Factors**	**Etiology**

• Both symptomatic and asymptomatic
• Severity can range from asymptomatic, white eye, with no staining to acute pain, photophobia, and redness
• Diffuse small, granular or crystal infiltrates
• Centrally located or all over cornea
• No edema
• Superficial
• Sterile
	• Distinct clinical entity
	• Contact lens-associated infiltrativs/infiltrative keratitis (CLAIK) associated with combination SiHy and MPS
	• No single ICD-9 code is appropriate and several listed (Table 2) may apply
		• May see between a few/month and up to 2/day
		• Fewer if practice no longer prescribes certain lenses or care solutions to new patients and moved existing patients away from them; cases are usually referrals for these practices
			• Originally saw some cases in late 80s and early 90s, then downswing
			• Began to see resurgence in late 2006, which possibly accelerated in 2007/2008
				• Often with Opti-Free Replenish and SiHys, but can see with other MPS
				• SiHys often Acuvue Oasys
				• Compliance (dirty lenses, lens over wear)
				• No rubbing
				• Bioburden
				• Younger patients/college students (though all ages at risk)
				• Tighter fit/poor tear film exchange "cesspool effect"
					• Multifactorial
					• Possible inflammatory response or delayed hypersensitivity to:
					  • MPS components such as preservatives (at high concentrations) and certain surfactants
					  • Bacterial components
					  • SiHy material

Table 5. Management of contact lens-associated infiltrates/infiltrative keratitis				
Treatment	**Dose**	**Follow-up**	**Resolution/ Resume Lens Wear**	**Regimen Change Post-treatment**
• Zylet (Bausch + Lomb) or Tobradex (Alcon), especially if severe • Lotemax (Bausch + Lomb) if steroid only • Pred Forte (Allergan) can be used for a short duration (3-5 days) only if NO suspicion of infectious etiology • Avoid use of steroids if any suspicion of infectious etiology	• Most QID • Some front load every 2hrs on day 1 then QID for 6 days	• Most 7 days • Some within 24-48 hrs if concerns of MK	• May be 7 to 14 days but patient dependent • Resolution within 3 days possible with aggressive tx (ophthalmic suspensions containing dexamethasone or prednisolone) • A few wait a week post-resolution of all symptoms • May be longer depending on patient	• Most change care solution first • Usually Clear Care or PHMB-based unless event occurred with PHMB-based MPS • Caveat: some patients go back to original MPS after trying Clear Care and experience recurrence

washing and drying ones hands before touching lenses and the ocular surface; using daily disposables for only one day and discarding after use; rubbing, rinsing, and storing in appropriately prescribed solutions, and frequent lens case replacement for re-usable lenses are all important. We typically include questions about hand-washing and case care during their annual comprehensive examination, but should also do so at every visit. Unfortunately, even with education, some patients will continue to be noncompliant. Recent studies show personality types might influence compliance. For example, the "risk taker" personalities tend to be less compliant to safety recommendations (Carnt, 2010). It's still is our professional responsibility to educate patients about the consequences of noncompliance, monitor compliance as best as we can, and finally, to utilize the safest treatment modalities for contact lens wear available based on science.

Dr. Myers: In cases where the patient is using an MPS or hydrogen peroxide-based lens care system and/or lens materials less commonly implicated, we find compliance with solutions to be the problem rather than it being the lens or solution itself. Usually, this is topping off solutions or with Clear Care, not replacing the case at appropriate intervals. We've also found noncompliance in patients using the Aquify Pro-Guard (Ciba Vision) lens case and this has caused CLAIK. We may be able to create a decrease in noncompliance with better patient education. But that said, some patients will believe their noncompliant friend or a blog post more than their doctor, especially if they can save money. Educating patients about the hazards of noncompliance of contact lens care is the key. Pictures of affected eyes from contact lens abuse or care solution sensitivities could help patients better understand the potential risks of noncompliance.

PATIENT MANAGEMENT

Dr. Shovlin: How do you manage cases of CLAIK?

Dr. Myers: Generally, I discontinue lens wear temporarily, and treat the inflammation. We use Tobradex or Pred Forte, either brand or generic give similar results. Usually 3 to 5 days is adequate. A few asymptomatic patients showed a couple subepithelial infiltrates on annual exams, which I simply treat by changing care solution and educating.

Dr. Sacco: I discontinue lenses and typically prescribe Lotemax for 1 to 2 weeks, but also will use Zylet. If a patient has had significant symptoms for a long time prior to presentation, I may prescribe Tobradex.

Dr. Eiden: We remove all patients from lenses. We treat cases of CLAIK with combination agents, typically Zylet QID, until all infiltrates are gone, and then taper the drops and reinstitute lens wear after they have been off drops for a few days. For cases of peripheral infiltrative keratitis, like the first case presented, treatment depends upon the whether an epithelial defect is present or not. If there is no significant epithelial defect or just some SPK over the infiltrate we would consider a combination agent, such as Zylet or Tobradex. If there is an epithelial defect we definitely take a different course of action.

Dr. Hom: This is my concern. There's a tendency in these cases to treat with antibiotics or steroid antibiotic combinations. I think the past trend is to over-treat with antibiotics. This trend has gotten us into trouble with MRSA and resistant strains. There are now strains that are resistant to ALL antibiotics because of overuse.

Dr. Shovlin: How do you manage the possibility of MK?

Dr. Sacco: To Dr. Hom's point, this is one reason I prefer not to prescribe an antibiotic, unless I have a clear indication it's infectious. I give them my on-

call contact information and tell them that if they have an increase in symptoms they are to call me ASAP. I also may see them in 24-48 hours if I'm concerned.

Dr. Cunningham: While I understand Dr. Hom's concern, I still prescribe a combination steroid/antibiotic, typically Zylet. It's a great consideration for two reasons. First, the antibiotic may help decrease bacterial load which may be aggravating the condition. Second, the damaged tissue from inflammation or mechanical causes can make the tissue more susceptible to infection.

Dr. Shovlin: Do you prescribe a new lens care solution first, new lenses first, or both?

Dr. Cunningham: Lens care solutions, then lenses if no co-morbidity is found.

Dr. Stiegemeier: I take a more conservative approach and usually change both.

Dr. Shovlin: I will sometimes use a different MPS and recommend a rub and rinse and frequent case replacement. But of great interest to me is that I've found a switch to peroxide with an MPS rinse in the morning using the same care solution they originally had a problem with seems to solve the problem.

Dr. Shovlin: If a patient is put in a new lens but with the same brand and new bottle of care solution, do the infiltrates recur? Does it take longer to manifest? (Table 4)

Dr. Sacco: Yes, the infiltrates recur if I re-challenge the patient with the same care solution. And no, from my experience it doesn't take longer … if anything, it's quicker.

Dr. Cunningham: Once a patient has had a case of CLAIK, I feel he or she is at a much higher risk regardless of contact lens or care solution. Changing lenses and/or care solutions is definitely reasonable to alter the biofilm characteristics and decrease the risk of a recurrent inflammation.

Dr. Shovlin: How often do patients have a recurrence in your practice?

Dr. Eiden: We're lucky that this is very, very rare since most patients comply with the changes we prescribe to the peroxide-based systems if we think that we're dealing with a care solution sensitivity etiology. If we think the etiology is a consequence of continuous wear, patients adhere to the prescribed daily wear schedule, as they really want to avoid having similar events reoccur.

Dr. Sacco: Not very often, because most times they are motivated to feel and see better.

Dr. Shovlin: Do any of the patients that you switch to a peroxide system switch themselves back to a multipurpose care solution? If so, why? (Table 5)

Dr. Eiden: Yes, they do occasionally. They may do this due to convenience or if they inappropriately used the peroxide and caused a peroxide keratoconjunctivitis.

Dr. Stiegemeier: Occasionally patients switch back to their original care solution and have a recurrence. They often see hydrogen peroxide systems as being more difficult to use. However, if they stay on a hydrogen peroxide-based system, there are no recurrences.

Dr. Shovlin: I would like to thank my colleagues who participated in this lively discussion. Based on our dialogue, I feel that several important risk factors have been identified as well as methods to improve the management of patients and reduce their likelihood of an infiltrative event. It's essential for us as clinicians to advocate for our patients and their ocular health by improving our skills as diagnosticians. However, it's important not to make overarching conclusions based solely on our experiences and what is read in the literature but rather apply them based on your clinical experiences and the patient's complete clinical picture. We sorely need additional research to answer many of the important questions raised today.

RESEARCH NEEDED TO SUPPORT CLINICAL IMPRESSIONS

Infiltrative keratitis is an inflammatory condition of the cornea, with an etiology that can be related to many things. The aforementioned group discussion has focused on the role of daily wear contact lens use in infiltrative keratitis, and particularly a possible growing frequency of occurrence of the condition. Likewise, some members of the group feel that these inflammatory events present differently than infiltrative keratitis as it has traditionally presented itself, and have termed the events "contact lens-associated infiltrates/infiltrative keratitis" or "CLAIK." It should be emphasized even though there have been several recent reports in both the trade and peer-reviewed literature and while some members of the panel discussed specific contact lens material or care solutions factors as being associated with these inflammatory events, this discussion is based on their clinical experience and observation. While these observations are critically important, they must be vetted by the scientific process before any causation can be attributed to any one specific product or factor involved in the process as only a few studies are clinical trials. Further, the frequency of the occurrence of the events likewise needs scientific confirmation. We look forward to bringing you further information about this important topic in the future.

REFERENCES

Ausubel FM. Are innate immune signaling pathways in plants and animals conserved? *Nat Immunol.* 2005;6:973-979.

Carnt NA, Evans VE, Naduvilath TJ, et al. Contact lens-related adverse events and the silicone hydrogel lenses and daily wear care systems used. *Arch Ophthalmol.* 2009;127:1616-1623.

Carnt N, Keay L, Wilcox M, Evans V, Stapleton F. Higher risk-taking propensity of contact lens wearers is associated with less compliance. *Cont Lens Anterior Eye.* 2010 Nov 4. [Epub ahead of print]

Diec J, Evans VE, Naduvilah TJ. Performance of Polyquad, PHMB and peroxide solutions with silicone hydrogel lenses. *Invest Ophthalmol Vis Sci.* 2009;50:E-abstract 5633.

Hong J, Bielory L. Allergy to ophthalmic preservatives. *Curr Opin Allergy Clin Immunol.* 2009;9:447-453.

Kislan T, Hom M. Corneal infiltrates with multipurpose solutions and contact lens combinations. *Invest Ophthalmol Vis Sci.* 2010;51:E-Abstract 3424.

Nikolic M, Kilvington S, Cheung S, Lam A, Brady N, Huth S. Survival and growth of Stenotrophomonas maltophilia in multipurpose contact lens solutions. *Invest Ophthalmol Vis Sci.* 2010;51:E-Abstract 1540.

Reeder R. Trends associated with corneal infiltrative events in soft lens wearers. Presented at the 2011 Global Specialty Lens Symposium; January 2011; Las Vegas, NV.

Reindel W, Cairns G, Bateman K. Using a meta-analysis to determine relationships between various safety parameters and lens care solutions. *Optometry.* 2009;80:Poster 10.

Sacco A. Silicone hydrogel contact lenses, lens care and sterile infiltrates: Is there a connection? Presented at the 2011 Global Specialty Lens Symposium; January 2011; Las Vegas, NV.

Sweeney D, Jalbert I, Covey M, et al. Clinical characterization of corneal infiltrative events observed with soft contact lens wear. *Cornea.* 2003;22:435-442.

Szczotka-Flynn L, Lass JH, Sethi A, et al. Risk factors for corneal infiltrative events during continuous wear of silicone hydrogel contact lenses. *Invest Ophthalmol Vis Sci.* 2010;51:5421-5430.

Ventocilla M, Wicker D. Contact lens complications. eMedicine. Available at: http://emedicine.medscape.com/article/1196459-print.

Yeung KK, Weissman BA. Presumed sterile corneal infiltrates and hydrogel lens wear: a case series. *Int Contact Lens Clin.* 1997;24:213-217.

Contact Lens SPECTRUM®

BAUSCH + LOMB™

HL-5084

SL6529